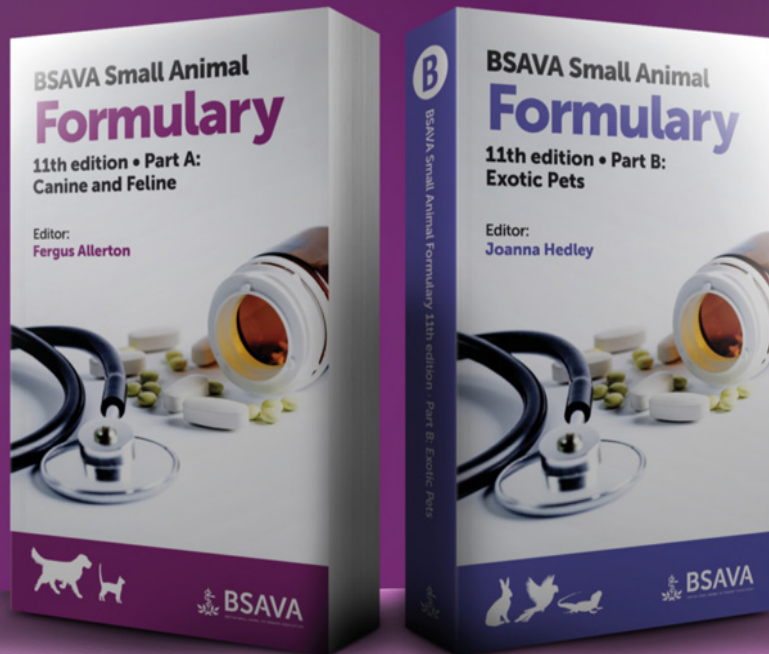

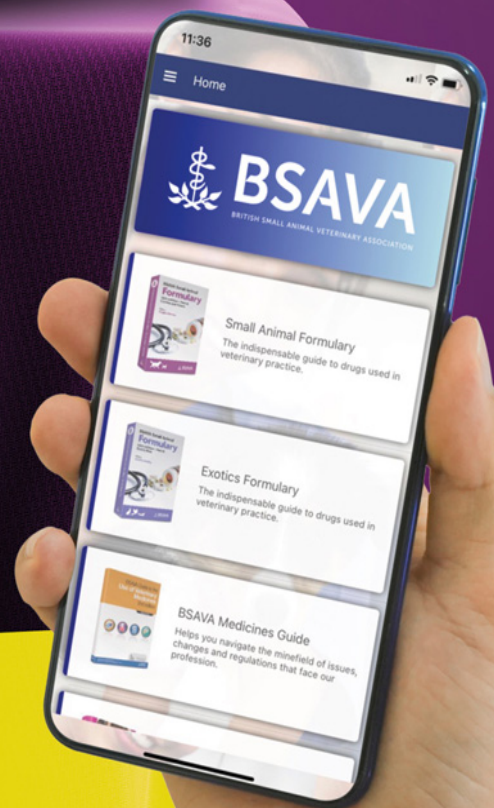Best in show



The NEW 11th edition BSAVA Small Animal Formularies are available NOW!

These two highly prized books are considered by the veterinary profession to be the most trusted and valued resources of their kind. Best in show for all the right reasons.

Order your copy today at
www.bsava.com/store



Now available on the BSAVA App!

Just one of our exclusive
BSAVA member benefits.

Join today at
www.bsava.com/membership

Curettage and diathermy: a treatment for feline nasal planum actinic dysplasia and superficial squamous cell carcinoma

R. H. JARRETT, E. J. NORMAN*, I. R. GIBSON† AND P. JARRETT‡

Pukekohe Veterinary Centre, 11 Edinburgh St, Pukekohe 2120, New Zealand

*Institute of Veterinary, Animal and Biomedical Sciences, Massey University, Private Bag 11222, Palmerston North 4442, New Zealand

†New Zealand Veterinary Pathology, PO Box 944, Waikato Mail Centre, Hamilton 3240, New Zealand

‡Department of Dermatology, Middlemore Hospital, Private Bag 93311, Otahuhu, Auckland 1640, New Zealand

OBJECTIVE: To evaluate curettage and diathermy as a treatment for actinic dysplasia and superficial squamous cell carcinoma of the feline nasal planum.

METHODS: Thirty-four cats clinically assessed to have actinic dysplasia and superficial squamous cell carcinoma involving less than 50% of the nasal planum were treated with a three-cycle curettage and diathermy procedure. Degree of dysplasia, response to treatment, adverse effects, owner perceptions, time to recurrence and proportion disease free at 1 year were evaluated.

RESULTS: Lesions ranged from actinic keratoses to invasive squamous cell carcinoma. A complete response to treatment was obtained in all cats. The median follow-up time was 18.2 (IQR: 12.0–22.8) months. Two cats had a clinical recurrence of lesions at 161 and 192 days after treatment. The probability of remaining disease free after 12 months was 0.94 (95% CI: 0.85–1.0). Median time to recurrence was not reached. The procedure was well tolerated with a good cosmetic outcome and no significant post-operative complications.

CLINICAL SIGNIFICANCE: This study suggests that curettage and diathermy is an effective treatment for feline actinic dysplasia and for superficial squamous cell carcinoma involving less than 50% of the nasal planum. Curettage and diathermy is an easily mastered technique, requiring minimal equipment.

Journal of Small Animal Practice (2013) **54**, 92–98

DOI: 10.1111/jsap.12025

Accepted: 7 December 2012

INTRODUCTION

Squamous cell carcinoma (SCC) is a common neoplasm of the head of cats, accounting for 50% of all cutaneous neoplasms in one study of feline skin cancer diagnoses in Perth, Australia, a region with high ambient UV radiation exposure (Burrows *et al.* 1994). It is more common in older cats, reflecting chronic exposure to UV radiation, with a predilection for the pinnae, nasal planum and eyelids of white cats or non-pigmented skin of dark-coloured cats (Macy & Reynolds 1981, Clarke 1991, Burrows *et al.* 1994). There can be a spectrum of lesions clinically and histopathologically from actinic dysplasia/keratosis (mild dysplasia), carcinoma in situ (full thickness epidermal dysplasia) to

invasive SCC. Additional tumours may arise on the nasal planum as a consequence of the entire area being exposed to UV light. Numerous treatments have been described including hyperthermia, external beam radiotherapy, nasal planum resection, cryotherapy, photodynamic therapy, intralesional chemotherapy, combined radiotherapy and intralesional chemotherapy, strontium-90 plesiotherapy and electrochemotherapy (Grier *et al.* 1980, Carlisle & Gould 1982, Withrow & Straw 1990, Clarke 1991, Peaston *et al.* 1993, Theon *et al.* 1996, Lana *et al.* 1997, de Vos *et al.* 2004, Goodfellow *et al.* 2006, Hammond *et al.* 2007, Spugnini *et al.* 2009). Many of these treatments are highly effective, however, not all are available in general veterinary practice because of their associated expense and the need for specialised equipment and training.

Curettage and diathermy is used by dermatologists in human medicine to treat selected non-melanoma skin cancers with high success (Ahmed *et al.* 2000, Reschly & Shenefelt 2010). The technique is considered suitable for use in actinic keratoses, carcinoma in situ and selected SCC and basal cell carcinomas of less than 1–2 cm diameter occurring in sites associated with a moderate to low risk of metastasis or recurrence (Goldman 2005). The tumour is vigorously scraped with the curette to remove friable tissue that sloughs easily until more resistant tissue is reached and pinpoint bleeding occurs in the wound bed (Sheridan & Dawber 2000). Diathermy of the entire base and circumference of the defect is then applied to a depth of 1–2 mm to extend the treated margin. Many authors recommend immediately repeating curettage and diathermy of the carbonised wound bed to further extend the treated margins for a total of two or three cycles (Sheridan & Dawber 2000) although the optimum number of cycles has not been well established (Goldman 2005). High cure rates of over 95% are reported for treatment of appropriately selected SCC lesions (Neville *et al.* 2007, Chren *et al.* 2011).

The success of curettage and diathermy in human patients suggests that this simple and rapidly performed technique could offer an appropriate and cost-effective treatment for cats with feline nasal actinic dysplasia and superficial SCC lesions. The primary aim of this study was therefore to evaluate the application of this technique to treat such cases; and a secondary aim was to assess owner acceptance of the procedure including post-operative care, comfort of the cat and cosmetic outcome.

MATERIALS AND METHODS

Cats were prospectively recruited for the study from veterinary practices in the Bay of Plenty, New Zealand between May 2005 and December 2007. This region (latitude 37° 40' S) has a sunny climate with an average of 2300 annual sunshine hours [National Institute of Water and Atmospheric Research, <http://cliflo.niwa.co.nz> (accessed 8 February 2011)]. The cats recruited in this study had unrestricted outdoor access.

The criteria for inclusion in the study were the presence of persistent erythema with crusting or superficial ulceration involving less than 50% of the area of the nasal planum, no evidence of metastasis as determined by palpation of the regional lymph nodes, agreement of the owners to participate in the trial and availability of the cat for follow-up. Cats subjectively assessed to have deeply invasive lesions of the nasal planum were excluded. Indicators for deep invasion were large, deeply and extensively ulcerated lesions. Cats with previously treated lesions were included provided they met the inclusion criteria.

Under general anaesthesia, pre-operative photographs were taken and the area of the lesion was estimated by measuring the two longest dimensions (length × width) with a surgical ruler. A single treatment with three cycles of curettage and diathermy was carried out. A 3-mm width bone curette (Surgicon, Sialkot, Pakistan) was used to curette the lesion. Friable tissue was removed by vigorous scraping of the deep and circumferential margins of the lesion until the curette met resistance against firm




FIG 1. 1-2mm tip for the thermal cautery unit.

tissue and no further tissue could be removed. Diathermy of the entire curetted bed was then applied using a thermocautery unit with a 1–2 mm diameter tip (Fig 1) (Geiger TCU; Geiger Medical Technologies, IA, USA) at a recommended setting of four (Lane *et al.* 2006) which is a medium setting (range 1–10) for this unit. This setting produced charring (confluent blackening of the wound bed) but not excessive burning. Curettage was immediately repeated to remove the carbonised tissue until bleeding points became apparent at which point diathermy was applied again. The cycle was repeated one further time to give a total of three sequential cycles during the procedure. Typically curettage of the cauterised wound bed removed minimal further tissue (<1 mm).

The area of the post-operative defect was estimated by measuring the two longest dimensions (length × width). Postoperatively cats were closely monitored for signs of discomfort and received buprenorphine (Temgesic; Reckitt Benckiser) (0.01mg/kg subcutaneously as a single dose) if required. Owners were instructed to report signs of pain such as rubbing of the face or inappetence. Petroleum jelly (Vaseline®, Unilever, Australia) was applied daily for at least 1 week by the owner to encourage moist wound healing. The fragments of tissue obtained by curettage were fixed in 10% formalin. Haematoxylin and eosin stained sections were assessed by one author (IRG) and classified according to the degree of dysplasia as normal, actinic dysplasia, carcinoma in situ or SCC.

Follow-up evaluations of the cats involved weekly clinical examinations giving the owners an opportunity to discuss any concerns. These were continued until the lesions were healed or until no further healing was observed over two consecutive weeks or ulceration progressed. Photographs were taken at each visit. Complete re-epithelialisation of the curetted bed constituted successful treatment. Incomplete re-epithelialisation of over 50% of the curetted area constituted partial remission and re-epithelialisation of less than 50% of the curetted area was defined as unsuccessful treatment. Thereafter 6-monthly examinations and

photography were undertaken until the censor date of December 2008 or until recurrence of the lesion. Owners were also instructed to contact one of the authors (RJ) if they noticed any lesion between scheduled re-examinations. Suspected recurrences were confirmed by histopathological examination of curetted tissue. Lesions were regarded as recurrent if they developed within or abutting the previously treated area. Owners of cats with recurrent lesions were offered all available treatment options including further curettage and diathermy for cases in which the recurrent lesion was superficial and involved less than 50% of the area of the nasal planum with no evidence of metastasis on lymph node palpation. A questionnaire was sent to the owners of all cats at 3 months postoperatively to determine their perception of the procedure and the outcome (Appendix 1).

All data were tabulated in Excel 2003 (Microsoft, Redmond, WA, USA). For cats that developed a second lesion in a new site at a later date, only data from the first lesion were included in the statistical analysis. Disease-free interval was calculated from the date of initial treatment until date of clinical assessment of recurrence. Cases that remained free of recurrence were censored at the date of the last follow-up evaluation or death of the cat. The follow-up time for all cats is reported as median and interquartile range (IQR). A Kaplan-Meier survival analysis was performed using SPSS 16.0 for Windows (SPSS Inc.; Chicago, IL, USA) to calculate the proportion disease free at 1 year with 95% confidence limits.

This study conformed to "The code of ethical conduct for the use of live animals for teaching and research" as approved under the New Zealand "Animal Welfare Act 1999."

RESULTS

Thirty-eight cats with nasal lesions were presented during the study period. Four of the 38 had extensive deep lesions suggesting highly invasive SCC and were not included in the study.

Thirty-four cats met the inclusion criteria. The age of 30 cats was known and was a mean of 11.6 years (range: 6–20 years). Fifteen cats were castrated males, 18 cats were spayed females; the gender of one cat was not recorded. Breeds included domestic shorthair ($n=30$), and domestic longhair ($n=4$). Eight cats had previously been treated with cryotherapy. The exact location of the previously treated lesions on the nose was unknown and therefore the lesions treated by curettage and diathermy may have been recurrent lesions or new lesions in these 8 cats.

Three cats were initially presented with two clinically distinct lesions. In two of these cats, curettage demonstrated that these lesions were contiguous and they were therefore treated as one lesion for the follow-up and statistical analysis. In the third cat, the two areas remained distinct after curettage so the endpoint used was recurrence in either area or the termination of the study.

The clinical presentation of the lesions included superficial erythematous scaling lesions, crusting and nodules with superficial ulceration. Histologically, 16 cats had actinic dysplasia, 9 cats had carcinoma in situ and 7 cats had SCC. Two cats with crusted lesions (approximately 3 mm² and 20 mm²) had no evidence of

dysplasia or neoplasia on examination of the curetted tissues and were reported as normal. The average measured pre-operative area of the lesions in all cats was 34 mm² (range: 2–225) and the average post-operative defect was 83 mm² (range: 20–308).

The typical healing process observed was a moist eschar which started to slough from 1 week postoperatively. Over the next 2–3 weeks re-epithelialisation occurred in all cats. Thirty-one cats were followed weekly during the first weeks after curettage and diathermy. The mean time to complete healing was 25 days (range: 17–35). An example of this healing process is shown in the sequence of photographs (Fig 2). There were no significant post-operative complications. In particular there was no post-operative infection or haemorrhage. One cat was observed rubbing its face after the procedure and was administered post-operative buprenorphine prior to discharge. Seven owners reported mild sneezing; in one case this was considered to be due to an upper respiratory tract infection unrelated to surgery. No post-operative nasal stenosis was observed.

The 34 cats were followed for a median of 18.2 (IQR: 12.0–22.8) months. Three cats died of unrelated causes at 108, 118 and 192 days and were known to have no recurrence of nasal lesions at the time of death. Two cats were lost to follow-up after examinations at 219 and 247 days at which they had no recurrence of lesions. One cat was censored at the termination of the study with no recurrence at 345 days. Two cats developed local recurrence of lesions at 161 and 192 days after treatment and in both cases the recurrence was noted close to the scheduled appointment. One of these cats had been previously treated with cryotherapy 1 year prior to the study. At initial presentation one of these two cats had a 28 mm² erythematous ulcer with a histological diagnosis of actinic dysplasia and the other had a 6 mm² crusted ulcer with a histological diagnosis of SCC. At recurrence both cases had histological diagnoses of SCC confirmed. Each was treated again with curettage and diathermy. As only two cases experienced recurrence in the course of the study, median time to recurrence was not reached. The probability of remaining disease free 12 months after therapy was 0.94 (95% CI: 0.85–1.0) (Fig 3).

All owners completed the questionnaire. Fifteen (47%) owners assessed their cat's post-operative pain as "no pain at all" or "little or no pain", nine (28%) owners assessed it as "slight" and eight (24%) as "moderate." Two owners were unable to accurately answer the pain question because of concurrent surgical procedures and were excluded from the analysis. Twenty-seven (79%) owners assessed the cosmetic outcome as "looks normal" or "almost normal." The care of the cat during the healing process was assessed "no problems at all" or "fairly easy" by 31 (91%) owners. Eight cats had previous cryotherapy. Of these eight cats, five owners (62%) subjectively considered that curettage and diathermy was less painful than the previous treatment, four (50%) considered healing was faster than the previous treatment and five (62%) thought that curettage and diathermy gave a better cosmetic outcome.

Four cats had extensive deep ulceration and did not meet the study criteria, however, their owners would not contemplate radical nasal resection and a three-cycle curettage and diathermy

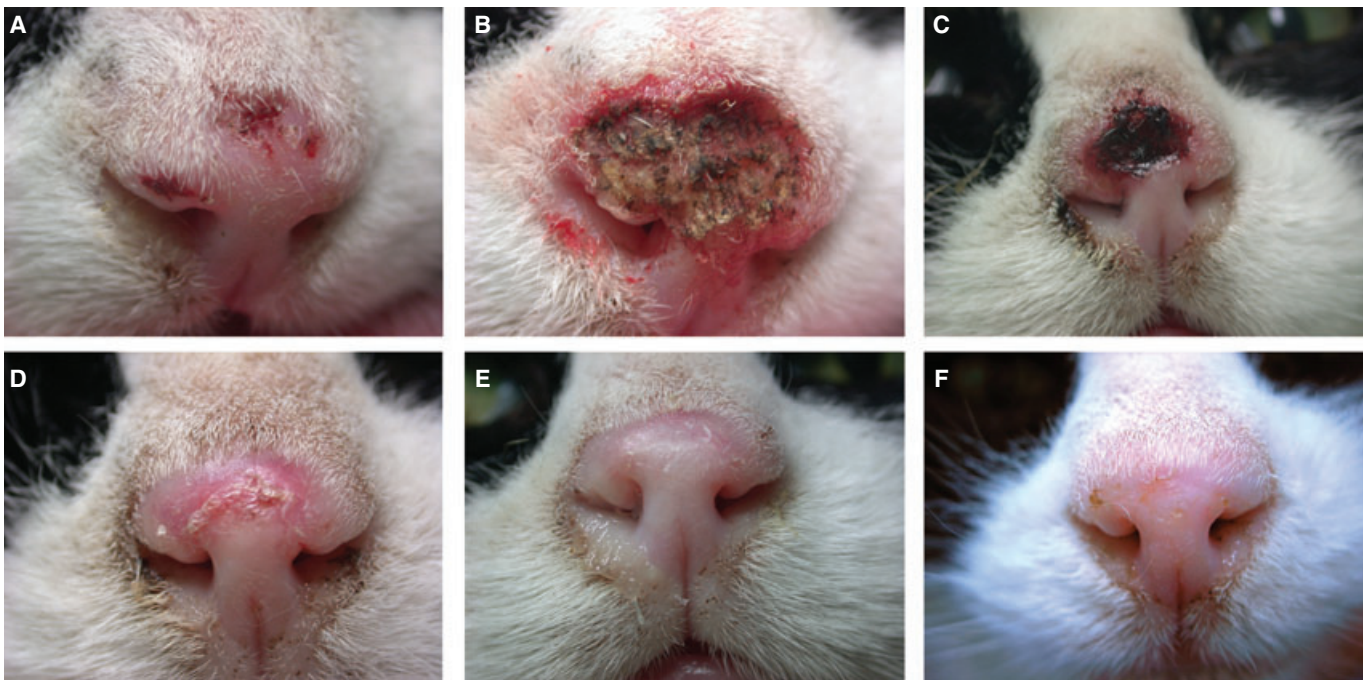


FIG 2. Sequence of pre-operative (A) and post-operative photographs of the nasal planum of a cat with squamous cell carcinoma of the nasal planum treated with curettage and diathermy. (B) immediate post-operative, (C) 11 days post-operative, (D) 18 days post-operative, (E) 34 days post-operative, (F) 18 months post-operative

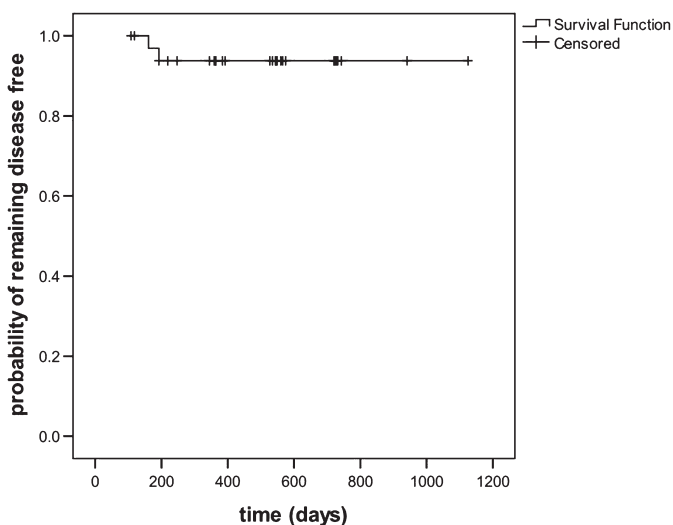


FIG 3. Probability of remaining disease free over time in 34 cats with actinic dysplasia and early squamous cell carcinoma of the nasal planum treated with curettage and diathermy (Kaplan-Meier method). The probability of remaining disease free 12 months after treatment was 0.94 (95% CI: 0.85–1.0)

treatment was performed. Two cats had a partial remission lasting 74 and 78 days after treatment. There was no response to a second treatment with curettage and diathermy in one of these 2 cats. In 2 cats treatment was successful. One of these 2 cats had a recurrence at 88 days and a second treatment with curettage and diathermy resulted in a complete remission lasting at least 574 days. The other cat had a recurrence at 147 days; there was no response to a second treatment.

DISCUSSION

This study investigated a previously unreported treatment option for a common condition in cats living in areas with high sun exposure and found it to be highly successful, simple to perform and well tolerated by cats and their owners.

Curettage and diathermy used in this study to treat feline actinic nasal lesions resulted in a 94% non-recurrence rate at 12 months after a single treatment. The mechanism of action of this treatment is as follows: heat generated in the tip of the thermocautery unit causes direct destruction of both cells and tissue blood supply to which it is applied. The curettage step serves to physically remove layers of tissue which increases the depth to which diathermy can be applied and also substantially increases the area treated beyond the initially estimated margin (Fig 2A, B). A clear delineation between tissue that curetted readily and tissue that was not easily removed was found in this study. Abnormal appearing nasal tissue was easily removed and then the curette “grated” against firm and apparently normal tissue and pinpoint bleeding developed. Occasionally normal appearing tissue also curetted easily until a point was reached where further curettage would not remove further tissue. This may indicate subclinical involvement of tissue which is visually normal but easily sloughs on curettage. Relative resilience to curettage of unaffected epidermal and dermal tissues compared to neoplastic and dysplastic tissue is described in human patients with non-melanocytic skin cancer (Sheridan & Dawber 2000) and curettage is thought to help delineate the extent of tumour (Goldman 2005). Thus, as well as enlarging the area treated, curettage appears to focus the subsequent diathermy on lesional margins and this likely con-

tributes to the high success rate of the treatment. Delineation of the extent of tumour with curettage may similarly be useful prior to other therapies such as cryotherapy or excision.

The success rate of curettage and diathermy in this study compares well with that of other treatments for superficial or minimally invasive feline nasal SCC lesions. An 87% complete response rate and median disease-free interval of 652 days was reported in 15 cats treated with strontium-90 plerotherapy (Goodfellow *et al.* 2006). In 55 cats treated with photodynamic therapy 85% achieved a complete response and the median disease-free interval was 157 days (Bexfield *et al.* 2008). Proton beam radiation treatment of 15 cats gave a 60% complete response rate with 64% remaining free of progression at one year (Fidel *et al.* 2001). In 18 cats with SCC (14 of which had nasal SCC lesions) complete remissions were obtained in 100% of cats treated with liposomal photosensitizer in combination with photodynamic therapy and the one year control rate was 75% (Buchholz *et al.* 2007).

Curettage and diathermy is suitable for use only in superficial and non-metastatic SCC because of the limited depth of penetration of diathermy. Careful selection of cases for treatment with this technique is thus important and would have contributed to the high success rate found in this study. This is not unexpected since many therapies studied report a higher success rate in early stage SCC lesions compared to more advanced lesions (Carlisle & Gould 1982, Withrow & Straw 1990, Peaston *et al.* 1993, Theon *et al.* 1995, Cunha *et al.* 2010). Alternative treatments, such as nasal planum resection (Lana *et al.* 1997) or combined intralesional carboplatin and radiotherapy (de Vos *et al.* 2004) would be expected to be superior for treatment of extensive invasive SCC of the nasal planum.

Only cats with lesions involving less than 50% of the area of the nasal planum were included in this study. This figure was chosen as a way of limiting the inclusion of advanced lesions, however, it is recognised that the depth of invasion and the histological grade would better indicate the suitability of cases for treatment with curettage and diathermy. Even if less than 50% of the area of the nasal planum is involved, the presence of signs which may indicate deep invasion, such as gross distortion of the nasal planum, suggest an individual case is unsuitable for treatment with curettage and diathermy. Should curettage reveal an unexpectedly deeply invasive tumour it does not preclude subsequent surgical excision and may help to delineate the extent of tumour. The unsuitability of curettage and diathermy for treatment of lesions involving more than 50% of the area of the nasal planum or with deep tissue involvement or nasal distortion was suggested by the early recurrence of disease in 3 of the 4 cats excluded from this study because of the presence of advanced lesions. Tumour destruction of the dermis can make curettage more difficult because it reduces the firmness of tissue to scrape against and the deep extent of the lesion is hard to determine (Goldman 2005). The effectiveness of curettage may therefore be reduced. While it would be tempting to extrapolate the results of this study to actinic keratoses and superficial SCC in other sites, it must be noted that differences in the resilience of underlying dermis may also affect the suitability of curettage and diathermy.

The mobile nature of eyelids may make curettage difficult and requires further study.

Humans undergoing curettage and diathermy are not routinely prescribed post-operative analgesia. However, in our study one quarter of owners (24%) reported moderate pain was experienced by their cat and one cat required immediate post-operative buprenorphine after veterinary assessment. Since these assessments were subjective these findings must be interpreted with caution. However, it is suggested that all cats undergoing therapy with curettage and diathermy should be given pre-emptive post-operative analgesia.

There are a number of reasons why the treatment may have failed in 2 cats in the present study, including differences in the biological behaviour of SCC or operator technique between cats. One of the two had previously been treated with cryotherapy for a nasal lesion and the exact site was unknown. It could be postulated that scarring from previous cryotherapy might limit curettage and therefore reduce the efficacy of therapy. However, the fact that 7 other cats in this study, which had good long-term responses to treatment with curettage and diathermy, had also had previous cryotherapy suggests there is no strong relationship between previous cryotherapy and treatment failure.

The curettage step provides the advantage of tissue for histopathological confirmation of the clinical diagnosis in contrast to cryotherapy during which biopsies are often not obtained in general practice (Clarke 1991). However, the tissue provided is fragmented and it can be difficult to orientate. Tumour depth and margins cannot be assessed and in this study the clinical severity of lesions did not always correlate with the histological diagnoses. In two cases the curetted fragments appeared normal histologically. The clinical behaviour of these two lesions was persistent and progressive, with erosion and crusting. The lesional tissue sloughed easily on curettage, which normal epithelium does not do, and was clearly delineated by normal-looking resilient tissue. While it cannot be confirmed that these lesions were actinic dysplasia or SCC lesions, this behaviour makes it clear that the tissue was not normal. Given the difficulty that can be experienced when examining tissue fragments which may have lost important structural relationships, the normal histopathology results in these two cases may represent false-negative results due to sampling issues. Examination of curetted tissue may thus not be 100% sensitive for diagnosis of some lesions.

The high cure rates obtained in our study and in studies of curettage and diathermy in non-melanotic skin cancers in humans (Sheridan & Dawber 2000) suggest that the curettage step does not increase the risk of deep dissemination of tumour cells. The action of curettage is to scrape rather than drive or incise. Subsequent diathermy of the wound bed effectively targets residual neoplastic cells.

This study had some limitations. Pre-operative staging was limited to palpation of local lymph nodes and pre-operative biopsies were not performed. This may have resulted in underestimation of the clinical stage of lesions presented but would not be expected to positively bias the success rate of therapy. There was no control group, and the characteristics of the studied population, although similar to those in other reports

of feline nasal SCC, may have influenced the success rate. As an unblinded study there is the potential for observer and owner bias, however, all suspected recurrent lesions were confirmed histologically. Some questionnaire responses relied on the owners' memory of events 3 months previously and owner perceptions of this period may have been positively influenced by a good final outcome. Weekly veterinary assessment during the recovery period, however, gave additional observations contemporaneously. It is possible that the 6-monthly revisit interval could have led to the time to recurrence being overestimated, even though owners were instructed to re-present cats earlier if they noticed any lesions. However, because all except two cats were disease free at their last assessment, the six monthly reassessment intervals did not lead to substantial inaccuracy in the estimate of the probability of remaining disease free at 12 months. Although the study was not long enough to reach the median survival time, cats were studied for a clinically relevant period of at least one year, and the study was sufficiently powerful to estimate the 1 year disease-free proportion within clinically useful confidence limits.

This preliminary study indicates that curettage and diathermy is an appropriate and effective technique for treatment of superficial SCC lesions involving less than 50% of the area of the nasal planum in cats. The majority (34/38) of cats that were presented had lesions which met the inclusion criteria and were considered suitable for treatment with a superficial therapy like curettage and diathermy and this may also be the case in other regions of the world where owners are well educated about skin cancers and the need for early intervention. Compared with other treatment modalities, curettage and diathermy offers several advantages including the need for only one anaesthetic and good owner acceptance. The technique is easily mastered and requires minimal equipment making it potentially widely available and affordable with the added advantage of tissues being routinely available for histological assessment. As cats may develop multiple lesions in a lifetime, curettage and diathermy could facilitate early treatment of small lesions in general practice, and reduce morbidity in feline nasal SCC.

Acknowledgements

The authors thank the Companion Animal Society of New Zealand for a grant to assist with the research. We also thank the veterinary practices and their clients in the Bay of Plenty, New Zealand who recruited cats to this study.

Conflict of interest

The authors confirm that all co-authors have given their permission to be listed. The authors confirm that the Companion Animal Society of New Zealand gives permission to be acknowledged in the paper.

References

- Ahmed, I., Berth-Jones, J. & Charles-Holmes, S. (2000) Comparison of cryotherapy with curettage in the treatment of Bowen's disease: a prospective study. *British Journal of Dermatology* **143**, 759-766
- Bexfield, N. H., Stell, A. J., Gear, R. N., *et al.* (2008) Photodynamic therapy of superficial nasal planum squamous cell carcinomas in cats: 55 cases. *Journal of Veterinary Internal Medicine* **22**, 1385-1389
- Buchholz, J., Wergin, M., Walt, H., *et al.* (2007) Photodynamic therapy of feline cutaneous squamous cell carcinoma using a newly developed liposomal photosensitizer: preliminary results concerning drug safety and efficacy. *Journal of Veterinary Internal Medicine* **21**, 770-775
- Burrows, A. K., Lee, E. A., Shaw, S. E., *et al.* (1994) Skin neoplasms of cats in Perth. *Australian Veterinary Practitioner* **24**, 11-15
- Carlisle, C. H. & Gould, S. (1982) Response of squamous cell carcinoma of the nose of the cat to treatment with x rays. *Veterinary Radiology* **23**, 186-192.
- Chren, M., Torres, M. P. H., Stuart, B. A., *et al.* (2011) Recurrence after treatment of nonmelanoma skin cancer: a prospective cohort study. *Archives of Dermatology* **147**, 540-546
- Clarke, R. E. (1991) Cryosurgical treatment of feline cutaneous squamous cell carcinoma. *Australian Veterinary Practitioner* **21**, 148-153
- Cunha, C. S., Carvalho, L. A. V., Canary, P. C., *et al.* (2010) Radiation therapy for feline cutaneous squamous cell carcinoma using a hypofractionated protocol. *Journal of Feline Medicine and Surgery* **12**, 306-313
- de Vos, J. P., Burm, A. G. O. & Focker, B. P. (2004) Results from the treatment of advanced stage squamous cell carcinoma of the nasal planum in cats, using a combination of intralesional carboplatin and superficial radiotherapy: a pilot study. *Veterinary and Comparative Oncology* **2**, 75-81
- Fidel, J. L., Egger, E., Blattmann, H. F. O., *et al.* (2001) Proton irradiation of feline nasal planum squamous cell carcinomas using an accelerated protocol. *Veterinary Radiology and Ultrasound* **42**, 569-575
- Goldman, G. (2005) Curettage and electrodesiccation. In: *Cancer of the Skin*. 1st edn. Eds D. S. Rigel, R. J. Friedman, L. M. Dzubow, D. S. Reintgen, J. C. Bystryn and R. Marks. Elsevier Saunders, Philadelphia, PA, USA. pp477-485
- Goodfellow, M., Hayes, A., Murphy, S., *et al.* (2006) A retrospective study of ⁹⁰Strontium plesiotherapy for feline squamous cell carcinoma of the nasal planum. *Journal of Feline Medicine and Surgery* **8**, 169-176
- Grier, R., Brewer, W. & Thielen, G. (1980) Hyperthermic treatment of superficial tumors in cats and dogs. *Journal of the American Veterinary Medical Association* **177**, 227-233
- Hammond, G. M., Gordon, I. K., Theon, A. P., *et al.* (2007) Evaluation of strontium Sr 90 for the treatment of superficial squamous cell carcinoma of the nasal planum in cats: 49 cases (1990-2006). *Journal of the American Veterinary Medical Association* **231**, 736-741
- Lana, S. E., Ogilvie, G. K., Withrow, S. J., *et al.* (1997) Feline cutaneous squamous cell carcinoma of the nasal planum and the pinnae: 61 cases. *Journal of the American Animal Hospital Association* **33**, 329-332
- Lane, J. E., O'Brian, E. M. & Kent, D. E. (2006) Optimization of thermocautery in excisional dermatologic surgery. *Dermatologic Surgery* **32**, 669-675
- Macy, D. W. & Reynolds, H. A. (1981) The incidence, characteristics and clinical management of skin tumours in cats. *Journal of the American Animal Hospital Association* **17**, 1026-1034
- Neville, J. A., Welch, E. & Leffell, D. J. (2007) Management of nonmelanoma skin cancer in 2007. *Nature Clinical Practice Oncology* **4**, 462-469
- Peaston, A. E., Leach, M. W. & Higgins, R. J. (1993) Photodynamic therapy for nasal and aural squamous cell carcinoma in cats. *Journal of the American Veterinary Medical Association* **202**, 1261-1265
- Reschly, M. J. & Shenefelt, M. D. (2010) Controversies in skin surgery: electrodesiccation and curettage versus excision for low-risk, small, well-differentiated squamous cell carcinomas. *Journal of Drugs in Dermatology* **9**, 773-776
- Sheridan, A. T. & Dawber, R. P. R. (2000) Curettage, electrocautery and skin cancer. *Australasian Journal of Dermatology* **41**, 19-30
- Spugnini, E. P., Vincenzi, B. & Citro, G. (2009) Electrochemotherapy for the treatment of squamous cell carcinoma in cats: a preliminary report. *The Veterinary Journal* **179**, 117-120
- Theon, A. P., Madewell, B. R., Shearn, V. I., *et al.* (1995) Prognostic factors associated with radiotherapy of squamous cell carcinoma of the nasal plane in cats. *Journal of the American Veterinary Medical Association* **206**, 991-996
- Theon, A. P., VanVechten, M. K. & Madewell, B. R. (1996) Intratumoral administration of carboplatin for treatment of squamous cell carcinomas of the nasal plane in cats. *American Journal of Veterinary Research* **57**, 205-210
- Withrow, S. J. & Straw, R. C. (1990) Resection of the nasal planum in nine cats and five dogs. *Journal of the American Animal Hospital Association* **26**, 219-222

APPENDIX 1

No.	Question	Possible responses
1.	How would you rate your cat's pain following surgery? (Please circle the number against the words that best describe the cat's pain).	1: No pain at all; 2: Little or no pain; 3: Slight pain; 4: Moderate pain; 5: Severe pain.
2.	How would you describe the cosmetic outcome of the treatment?	1: Looks normal; 2: Almost normal; 3: Slightly disfiguring; 4: Disfiguring; 5: Very disfiguring.
3.	How difficult did you find the care of your cat during the healing process?	1: No problems at all; 2: Fairly easy; 3: Some problems; 4: Difficult; 5: Very difficult
4.	Has this cat had previous treatment for cancer on its nose?	1: Yes; 2: No; 3: Don't know. (if 'yes' answer q5-9; if 'no' or 'don't know', you do not need to answer any more questions. Thank you for your help!)
5.	Did your cat have surgery (part of its nose cut off)?	1: Yes; 2: No; 3: Don't know.
6.	Did your cat have its nose frozen (cryotherapy)?	1: Yes; 2: No; 3: Don't know.
7.	Compared with the previous treatment for cancer of the nose, this latest treatment was:	1: Less painful; 2: About the same; 3: More painful; 4: Don't know.
8.	Compared with the previous treatment for cancer of the nose, the healing time for this latest surgery was:	1: Quicker; 2: About the same; 3: Slower; 4: Don't know.
9.	Compared with the previous treatment for cancer of the nose, the cosmetic outcome or final appearance of the nose, after healing was complete, for this latest surgery was:	1: Better; 2: About the same; 3: Worse; 4: Don't know.

Questionnaire completed by owners of 34 cats 3 months after treatment of the cats' nasal actinic dysplasia or squamous cell carcinoma with curettage and diathermy.